

In the name of God



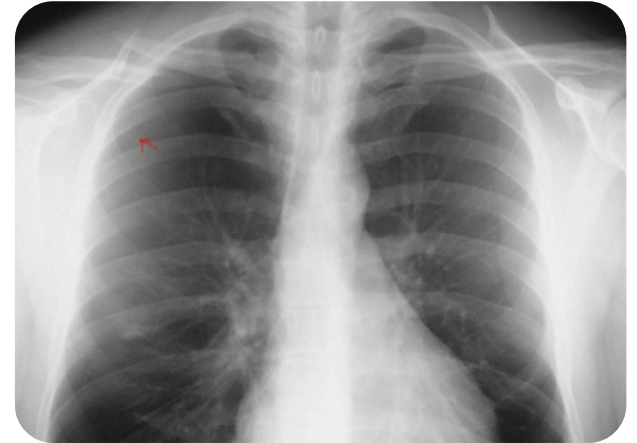
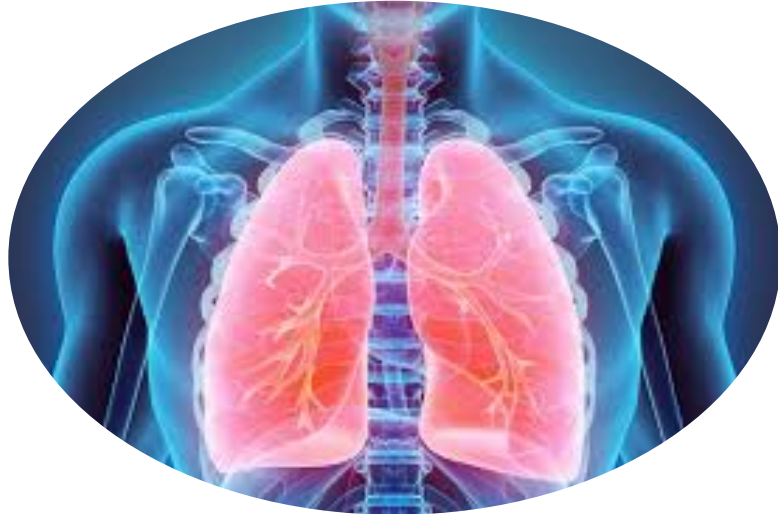**Secondary tension
pneumothorax in a COVID-19
pneumonia patient**

Provider: Rasoul khaledi

Advisor: Dr.rasoul raesi



pneumothorax





introduction

As we do know the lung is one of our major organ in our body and the primary organ in our respiratory system which is separated from the chest by a double membrane:parietal and visceral membrane.

Between this two layer there is a space that we call it plural space which contain 10-15cc of plural fluid.

If one of these layer pierced and Establish a connection between the side space

and the outside environment air will collect in this space that we call it

pneumothorax



Type of pneumothorax

There are 3 types of pneumothorax:

- . simple pneumothorax**
- . traumatic pneumothorax**
- . Tension pneumothorax**



Simple pneumothorax

It occurs when there is intermittent positive pressure ventilation

which is caused spontaneously or as a result of non-penetrative injuries. Basically, it is not life-threatening for the patient, but there is a possibility of developing tension pneumothorax



Traumatic pneumothorax

- **This occurs when an injury to the chest (as from a car wreck or gun or knife wound) causes the lung to collapse.**



Tension pneumothorax

It occurs when pressure inside the pleural cavity is greater than the outside atmospheric pressure. It can force the entire lung to collapse and can push the heart toward the lung, putting pressure on both.

And it could be the cause the lung and superior vena cava and inferior venacava to collapse.



Symptoms

1-expansion of neck veins

2-Deviation of the mediastinum to the opposite side

3-reduce the respiratory sound On the affected side of the lung

4-in tension pneumothorax Tracheal deviation to the unaffected side



Treatment

- 1-administer O2 with 10-15L/Min which applied with the Partial Rebreathing Mask**
- 2-monitoring,ECG,check vital sign**
- 3- reduce the pressure in tension pneumothorax immediately by inserting a catheter through a mini open tracheotomy in the 2nd and 3rd intracoastal space in mid clavicular line.**
- 4-In mild cases, symptomatic treatment.but in**