

Case Report

Fat Embolism Syndrome, a Diagnostic Dilemma: Case Report and Review of the Literature

Rhita Salah Réda El Alami Badr Chalouah Mohammed Benchakroun
Abdeloihab Jaafar Salim Bouabid

Department of Orthopedic Surgery and Traumatology, Military Hospital Mohammed V,
Rabat, Morocco

Keywords

Fat embolism · Femur fracture · Gurd

Abstract

Fat embolism syndrome (FES) remains a diagnostic dilemma on a world scale. It has a variable degree of presentation, which makes the diagnostic confirmation hard to obtain. FES is a life-threatening condition which is usually associated with orthopedic trauma, particularly long bones fractures whose early fixation helps in preventing it. It requires supportive care, and no specific treatment is needed. Here, we report the case of a FES in a 20 year-old male patient with right femoral shaft fracture following a motorbike accident, which is diagnosed by Gurd's criteria and confirmed after exclusion of other diagnosis with similar clinical presentation.

© 2021 The Author(s).

Published by S. Karger AG, Basel

Introduction

Fat embolism syndrome (FES) is a rare condition where circulating fat emboli are responsible for a variable degree of presentation, ranging from mild symptoms to severe multi-system dysfunction. It is a diagnosis of exclusion that keeps challenging trauma clinicians since it was first described in 1862 by Zenker [1]. The aim of our study is to highlight this mysterious syndrome through a case report and discuss it in the light of the literature.

Case Report

A 20 year-old man, without medical history, was referred to the emergency department showing a right thigh injury following a motorbike accident. On initial presentation (6 h after injury), our patient was alert, oriented, and stable. Physical examination revealed a painful

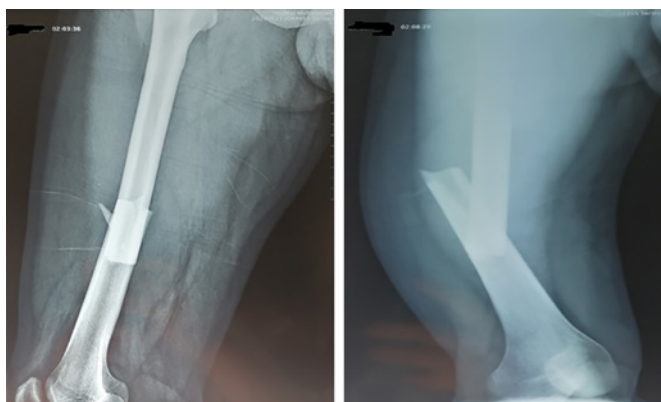

Fig. 1. Standard X-ray imaging of the right thigh in antero-posterior (left) and lateral (right) views showing a displaced transverse fracture of the right femoral shaft.

and swollen right thigh, with a punctate wound of the anterior side of the thigh. All pulses, including popliteal, posterior tibial, and dorsalis pedis were palpable. Nerve examination showed no sensory-motor deficit. Standard X-ray imaging of the right thigh in antero-posterior and lateral views showed a displaced transverse fracture of the right femoral shaft (shown in Fig. 1). Since it was a high-energy trauma, a full body scan was performed and helped rule out further associated injuries. The patient was admitted to the operating room 8 h after injury and underwent, under spinal anesthesia, closed intramedullary nailing with wound debridement (shown in Fig. 2). Twenty-four hours after surgery, the patient developed dyspnea with an oxygen saturation between 90 and 93% under room air and a tachycardia above 110 beats per minute. His temperature was 36.2°, and he remained conscious with a GCS of 15. Moreover, a skin exam found petechia of the buccal mucosa (shown in Fig. 3). Laboratory tests showed acute drop in hemoglobin and hematocrit despite minimal intraoperative blood loss. The platelet count was normal (Table 1). The chest X-ray was normal. A pulmonary embolism was highly suspected, and a heparin infusion was started; then, a contrast enhanced chest CT scan was performed. It did not reveal any findings of pulmonary embolism, yet there was a bilateral and diffuse crazy-paving pattern. It should be noted that this radiologic appearance was absent on the initial full body scan (shown in Fig. 4). Heparin was then discontinued. Considering the severity and nonspecific nature of coronavirus disease symptoms, and in order to rule out this diagnosis, the patient was tested negative for COVID-19 twice using the RT-PCR test and serology. He received supportive care using supplemental oxygen and blood transfusion but did not benefit from corticosteroid therapy; then, he was kept under medical surveillance until symptoms have disappeared. Finally, diagnosis of FES was stated by the association of 2 major criteria which are dyspnea and petechia and 2 minor criteria which are anemia and tachycardia, after having eliminated pathologies with similar symptoms. After 3 weeks spent at the hospital, the patient was discharged and then reviewed 2 weeks, 1 month, and 6 months later. He remained alert with stable vital signs, and no complications were observed.

Discussion

FES is a rare complication that usually occurs in patients with orthopedic trauma, more often with long bone fractures of the lower extremities. Femur is the most frequent, followed by the pelvis. Male preponderance is striking, and the average age is between 10 and 40 years [2].

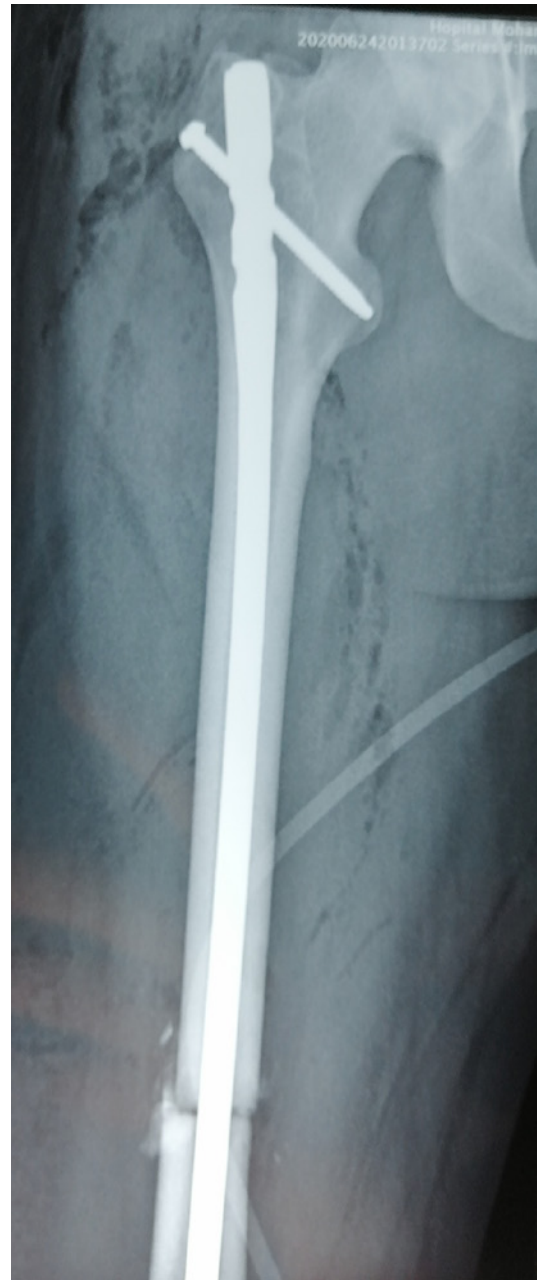


Fig. 2. Standard X-ray imaging of the right thigh after closed intramedullary nailing.

Even though the pathophysiology remains uncertain, 2 mechanisms are often described: the mechanical one where intramedullary pressure increases and forces marrow to pass into injured venous sinusoids, causing fat droplets to be released into the venous system and then to the lungs and systemic vasculatures. The occlusion of pulmonary capillaries is responsible for interstitial hemorrhage and alveolar collapse which leads to the hypoxemic vasoconstriction. Besides lung injury, these fat droplets can enter the arterial circulation which explains neurologic and dermatologic manifestations. The second theory is biochemical, based on a proinflammatory states where local hydrolysis of triglyceride emboli by tissue lipase produces glycerols and free fatty acids, which leads to the development of a vasogenic and cytotoxic edema and hemorrhage responsible for acute lung injury, because of their toxicity to endothelial cells and pneumocytes [3].

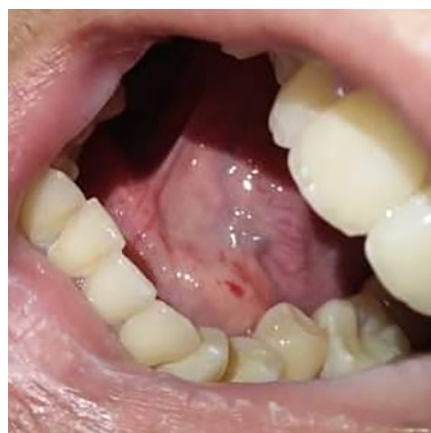

Fig. 3. Clinical photography showing petechia of the buccal mucosa.

Table 1. Laboratory data

	Normal range	2 h before surgery	4 h after surgery	24 h after surgery	72 h after surgery
Hemoglobin, g/dL	13–17	13.9	11.1	7	9.4
Hematocrit, %	41–53	42	32.9	20.8	26.9
Platelet count, $10^3/\mu\text{L}$	150–400	209	162	196	181

FES seems to occur within 48 h after injury. It is a diagnosis of exclusion based on clinical factors including long bone and pelvic fracture, osteomyelitis, pancreatitis, bone tumor lysis, and lipid infusion and exclusion of other diagnoses with similar clinical presentation such as pulmonary embolus, pneumonia, aortic dissection... [4]. Clinical presentation is associated with the triad of signs including respiratory involvement, neurologic manifestations, and petechial rash. Dyspnea is the earliest and most predominant symptom, along with tachypnea and arterial hypoxemia. Neurologic manifestations are nonspecific but frequent, ranging from simple headache or acute confusion to seizures and coma. Petechial rash is present in approximately 50% of patients, and it is typically distributed in the head, neck, anterior thorax, axillary region, conjunctiva, and buccal mucosa. This triad is part of Gurd's criteria along with tachycardia, pyrexia, jaundice, and renal and retinal changes. Gurd's criteria are the most widely used, and to state the diagnosis of fat embolism syndrome, a combination of at least 2 major criteria or 1 major criterion and 2 minor criteria is required [5].

Laboratory test results are nonspecific. They may show acute anemia and thrombocytopenia [6]. Identification of fat droplets in macrophages obtained during a broncho-alveolar lavage may be a rapid method for the diagnostic confirmation [7].

The diagnosis of FES may be oriented by radiological findings, even though none is specific. Chest radiographs are often normal although they may show diffuse bilateral patchy infiltrates related to acute respiratory distress syndrome. CT pulmonary angiogram mostly helps exclude pulmonary emboli, yet, it may reveal ground-glass opacity. MRI of the brain is widely used in patients with FES suspicion. It can detect diffuse and hyperintense lesions in white and gray matter on T2-weighted images. However, these lesions may take few days to appear, which explains the normality of the MRI findings during the acute phase [8].

Treatment is supportive based on management of symptoms, such as hypoxemia using supplement oxygen or even mechanical ventilation when needed, and maintenance of blood volume as well as correct hemodynamic status in order to avoid exacerbation of lung injury. Patients with neurologic damage require close monitoring of intracranial pressure [9].

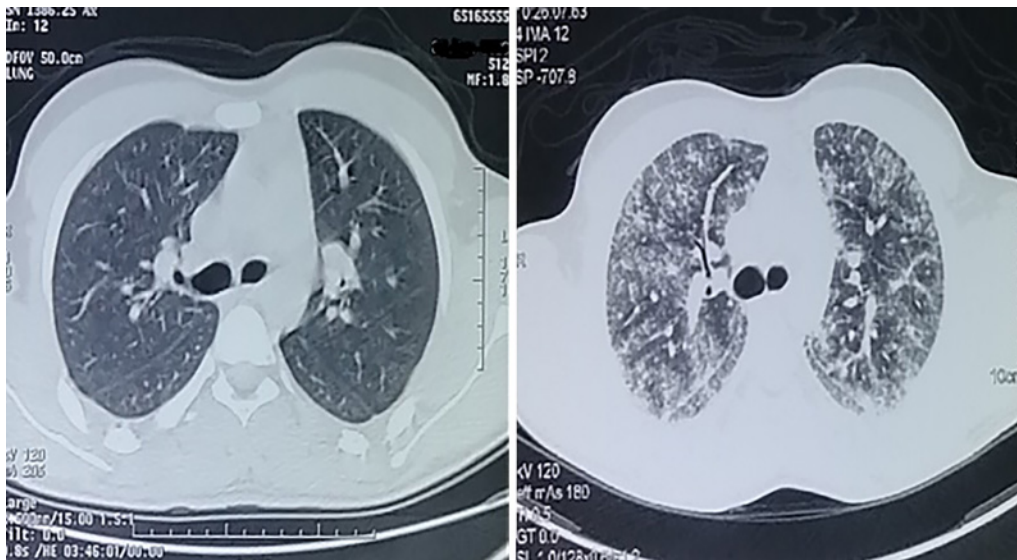


Fig. 4. Chest CT scan: normal, when patient was admitted (left) – diffuse crazy-paving pattern (right).

FES is associated with a mortality rate of 5–15%, the reason why prevention is of paramount importance. Early fracture fixation is the key to avoiding this syndrome, by stopping more fat droplets to be released into the circulation. Also, surgical techniques may have an important impact on the development of the syndrome; for instance, external fixation or fixations using screws and plates are less risky than intramedullary nailing [10]. According to a meta-analysis of Cavallazzi, corticosteroids reduce the incidence of FES after long bone fractures of the lower limb. The effect of corticosteroids may be correlated to inhibition of the inflammatory reaction to free fatty acids and platelet aggregation [11].

Conclusion

FES remains a diagnostic challenge due to its variable presentation ranging from mild symptoms in benign cases to severe multisystemic dysfunction as a life-threatening condition. A combination of clinical, biological, and radiological findings assists the clinician with the diagnosis of FES and only confirmed when other pathologies with similar presentation are ruled out. Treatment is mainly supportive, and prevention is the key.

Statement of Ethics

The patient gave his written informed consent to publish this case including the images.

Conflict of Interest Statement

The authors declare no conflicts of interest.

Funding Sources

No funding was received by authors.

Author Contributions

Rhita Salah: conception and design of the work and drafting the work. Réda El Alami: conception and design of the work and drafting the work. Badr Chalouah: analysis and interpretation of the data for work. Mohamed Benchakroun: revising the work for important intellectual content. Abdeloihab Jaafar: revising the work for important intellectual content. Salim Bouabid: revising the work for important intellectual content.

References

- 1 Zenker FA. *Beiträge zur normalen und pathologischen Anatomie der Lunge*. G. Schönfeld (CA Werner); 1862.
- 2 Kirk A, Elliott J, Varma D, Kimmel LA. Fat embolism syndrome: experience from an Australian trauma centre. *Int J Orthop Trauma Nurs*. 2020 Feb;36:100746.
- 3 Kosova E, Bergmark B, Piazza G. Fat embolism syndrome. *Circulation*. 2015;131(3):317–20.
- 4 Mimos O, Incagnoli P, Edouard A, Samii K. Le syndrome d'embolie graisseuse. In: Samii K, editor. *Traité d'anesthésie réanimation chirurgicale*; 1997. vol. 2; p. 1651–6.
- 5 Gurd AR, Wilson RI. The fat embolism syndrome. *J Bone Joint Surg Br*. 1974;56(3):408–16.
- 6 Uransilp N, Muengtawepong S, Chanalithichai N, Tammachote N. Fat embolism syndrome: a case report and review literature. *Case Rep Med*. 2018 Apr 29;2018:1479850.
- 7 Chastre J, Fagon JY, Soler P, Fichelle A, Dombret MC, Hutten D, et al. Bronchoalveolar lavage for rapid diagnosis of the fat embolism syndrome in trauma patients. *Ann Intern Med*. 1990 Oct 15;113(8):583–8.
- 8 Shaikh N, Parchani A, Bhat V, Kattren, MA. Fat embolism syndrome: clinical and imaging considerations: case report and review of literature. *Indian J Crit Care Med*. 2008 Jan;12(1):32–6.
- 9 Berdai AM, Shimi A, Khatouf M. Le syndrome d'embolie graisseuse post traumatique [Post-traumatic fat embolism syndrome]. *Pan Afr Med J*. 2014;17:83.
- 10 Powers KA, Talbot LA. Fat embolism syndrome after femur fracture with intramedullary nailing: case report. *Am J Crit Care*. 2011;20(3):267–6.
- 11 Cavallazzi R, Cavallazzi AC. O efeito do corticosteroíde na prevenção da síndrome da embolia gordurosa após fratura de osso longo dos membros inferiores: revisão sistemática com meta-análise [The effect of corticosteroids on the prevention of fat embolism]. 2008.