

Available online at www.sciencedirect.com

ScienceDirect

journal homepage: www.elsevier.com/locate/radcr

Case report

Right atrial clot and pulmonary embolism in a patient with COVID-19: A case report [☆]

Entezar Mehrabi Nasab^a, Siamak Heidarzadeh^b, Seyyed Shamsadin Athari^{c,*}

^a Department of Cardiology, School of Medicine, Tehran Heart Center, Tehran University of Medical Sciences, Tehran, Iran

^b Department of Microbiology and Virology, School of Medicine, Zanjan University of Medical Sciences, Zanjan, Iran

^c Department of Immunology, School of Medicine, Zanjan University of Medical Sciences, Zanjan, Iran

ARTICLE INFO

Article history:

Received 5 June 2021

Revised 5 August 2021

Accepted 6 August 2021

Available online 13 August 2021

Keywords:

COVID-19

Embolism

Atrial clot

ARDS

Coronavirus

ABSTRACT

The infection caused by the novel coronavirus (COVID-19) immersed the globe into a widespread pandemic. The disease leads to acute respiratory disease syndrome, hyper-coagulation, and cardio-vascular diseases. In this case report, we presented an 80-year-old man with right atrial clot and acute pulmonary embolism, who was diagnosed with COVID-19. The patient was isolated and transferred to the intensive care unit with a diagnosis of submassive pulmonary thromboembolism and right atrial clot following COVID-19 infection. Antibiotics and anticoagulants were administered, and the patient was referred for mechanical thrombectomy. He did not die and after recovery, was discharged with warfarin administration.

Preventing thromboembolic events seems to be the first priority in the management of COVID-19 patients. It is necessary to look for strategies to manage and prevent the early occurrence of thromboembolic events in these patients.

© 2021 The Authors. Published by Elsevier Inc. on behalf of University of Washington.

This is an open access article under the CC BY-NC-ND license

(<http://creativecommons.org/licenses/by-nc-nd/4.0/>)

Introduction

The virus causing the COVID-19 infection is a single-stranded RNA coronavirus, which led to the recent pandemic in the world. The disease mainly leads to acute respiratory distress syndrome (ARDS) in patients. However, its other complications include endothelial dysfunction, a

hyper-coagulation state, thromboembolic events, and vascular diseases [1, 2]. Vascular complications such as myocardial ischemia, ischemic stroke, systemic arterial thrombi, pulmonary thromboembolism, and deep vein thrombosis have been reported [3-5]. In this report, we described an 80-year-old man with acute pulmonary embolism and right atrial clot, presenting with the signs of the novel coronavirus pneumonia.

[☆] Competing Interests: The authors declared no conflict of interest.

* Corresponding author.

E-mail address: SS.Athari@gmail.com (S.S. Athari).

<https://doi.org/10.1016/j.radcr.2021.08.015>

1930-0433/© 2021 The Authors. Published by Elsevier Inc. on behalf of University of Washington. This is an open access article under the CC BY-NC-ND license (<http://creativecommons.org/licenses/by-nc-nd/4.0/>)

Table 1 – Laboratory findings of a COVID-19 patient presenting with right atrial clot and pulmonary embolism.

Parameters	Result	Normal range	Unit
Hematocrit	50.9	41-52	%
Hemoglobin	15.2	12-16	g/dL
Red blood cells	7.71	4.70-6.10	10 ⁶ /μL
White blood cells	20.3	4.50-11	10 ³ /μL
Neutrophils	80%	35-70	%
Lymphocytes	2%	20-50	%
Platelet count	177	150-450	10 ³ /μL
Sodium	137	135-145	mmol/L
Potassium	4.2	3.5-5.1	mmol/L
Glucose	210	70-100	mg/dL
D-dimer	>10	0-0.45	ug/mL
C-reactive protein	23	Less than 1.0	mg/dL
Troponin	0.02	0-0.8	ng/mL
Aspartate transaminase	50	17-60	U/L
Alanine aminotransferase	46	0-49	U/L
Creatinine	2.7	0.5-1.20	mg/dL
Blood urea nitrogen	99	12-45	mg/dL

Case report

An 80-year-old Iranian man was admitted to the emergency department of our care center with acute severe dyspnea at rest, dry cough, feeling ill, and fever. The symptoms persisted for the past 10 hours. The patient's past history revealed type 2 diabetes mellitus, chronic renal failure (CRF), and coronary artery disease. Clinical examination and checking his vital signs showed normal blood pressure (BP = 110/75 mm Hg), fever (39°C), tachycardia (heart rate = 100), tachypnea (respiratory rate = 24 cycles per minute), and hypoxemia (peripheral O₂ saturation of 85% while breathing into the ambient air). Oxygen saturation improved by administering supplemental oxygen via the nasal cannula. There were bilateral diffuse coarse crackles on auscultation. He was evaluated for the COVID-19 infection by reverse-transcriptase polymerase chain reaction (RT-PCR) test. Also, routine blood tests, pulmonary computed tomography scanning (CT-scan), electrocardiography (ECG), and transthoracic echocardiography (TTE) were performed.

The COVID-19 PCR test was positive, and his laboratory findings showed elevated levels of WBC, LDH, and Cr, as well as negative troponin (Table 1). The CT scan showed round-glass opacities in both lungs (Fig. 1). There were no signs of pericardial or pleural effusion. The ECG showed sinus tachycardia, right axis deviation, right ventricular strain pattern (T wave inversion in the right precordial and inferior leads), the S1Q3T3 pattern, incomplete Right Bundle Branch Block, and a dominant R wave in V1 (Fig. 2). Normal left ventricular size, mild systolic dysfunction (LVEF = 50%), D-shape LV, and paradoxical septal motion were noted in TTE. Moderate right ventricular enlargement and mild to moderate systolic dysfunction were also observed. The left atrium had a normal size. However, the right atrium was dilated and contained a large (20-mm diameter) and highly mobile thrombus extending across the tricuspid valve into the right ventricle. Also, mild mitral regur-

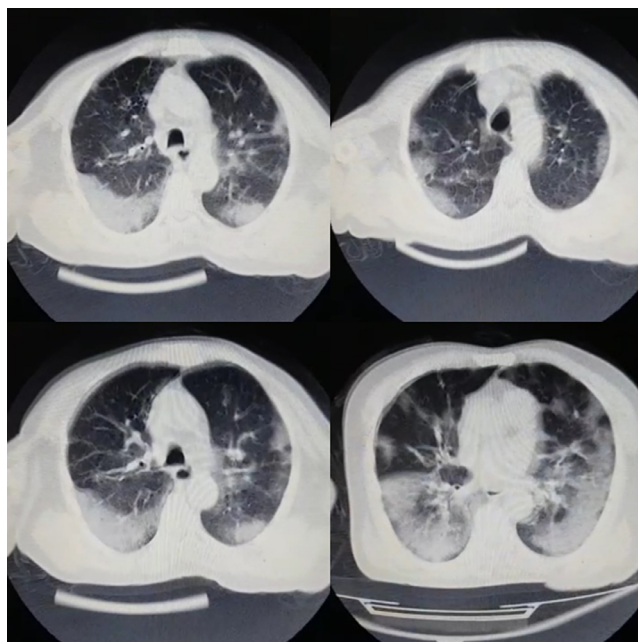


Fig. 1 – The computed tomography-scan of the patient, showing round-glass opacities in the lung.

itation (MR), moderate tricuspid regurgitation (TR) with pulmonary hypertension (TRG = 45, PAP = 45-50 mm Hg), moderate pulmonic regurgitation (PR), and dilated main pulmonary artery were observed (Fig. 3). Pulmonary CT angiography confirmed pulmonary thromboembolism (PTE). Thrombotic lesions were distributed in the peripheral arteries of both lungs. Doppler ultrasound revealed no deep vein thrombosis (DVT) in lower limbs. The patient was isolated and transferred to the intensive care unit with the diagnosis of submassive PTE, RA clot, and coronavirus pneumonia. Antibiotics and anticoagulants were administered. The patient was a surgery candidate and was referred for mechanical thrombectomy. He did not die and survived, after recovery and control of COVID-19, the patient was discharged with warfarin administration.

Discussion

The novel coronavirus seems to increase the risk of thrombotic complications. The pathophysiological mechanisms of thrombosis include immobilization, hypoxia, inflammation, endothelial dysfunction, and a hypercoagulable state. The virus activates the inflammatory response, induces the release of inflammatory factors by the endothelium, and triggers hemostatic systems, resulting in diffuse endothelial inflammation and microvascular dysfunction, which can finally lead to widespread thrombosis [6]. The acute phase of the COVID-19 infection is associated with a cytokine storm that can trigger thromboembolic events in the early stages of the disease. [7]. In our patient, thromboembolism occurred in the acute phase of the COVID-19 infection. At the time of COVID-19 diagnosis, the symptoms of RA clot and PE were also observed.

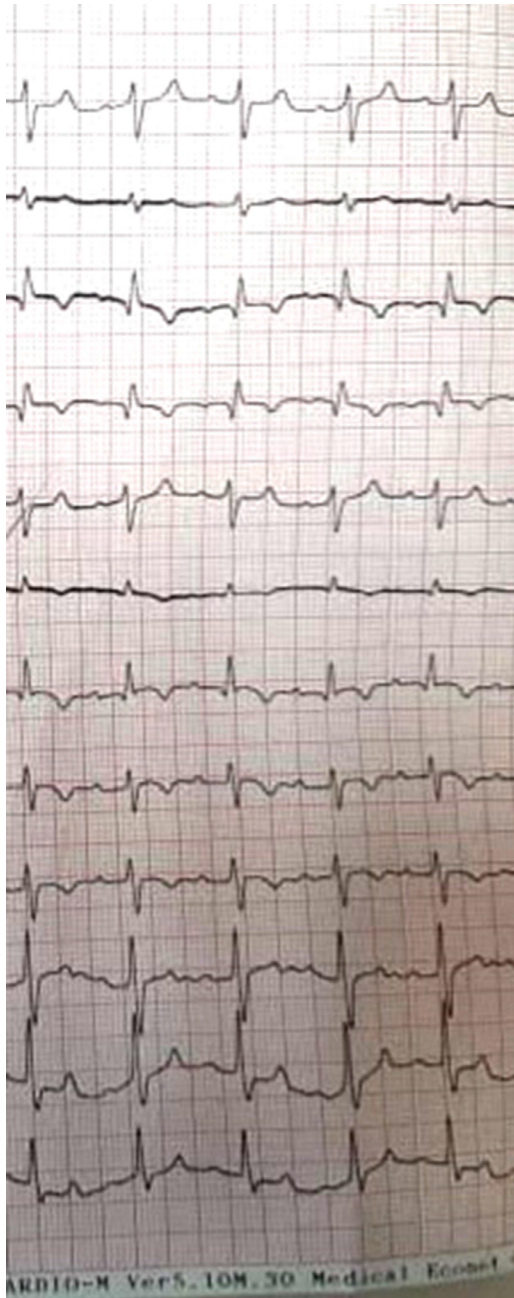

Fig. 2 – The electrocardiography of the patient.

The patient had no recent hospitalization records, immobility, or other acute pulmonary embolism risk factors. Therefore, it seems that the main culprit of the thromboembolic event in our patient was the COVID-19 infection. The diagnosis of the novel coronavirus infection coincided with embolism, making the condition more complicated for administering prophylactic agents for thromboembolism.

Klok et al. argued that PTE phenotype in patients with the novel coronavirus infection was different from that of patients without coronavirus infection, noting that thrombotic lesions in COVID-19 patients were distributed in the peripheral arteries of lungs [8]. The results of Pulmonary CT angiography in our patient were consistent with the results of the recent

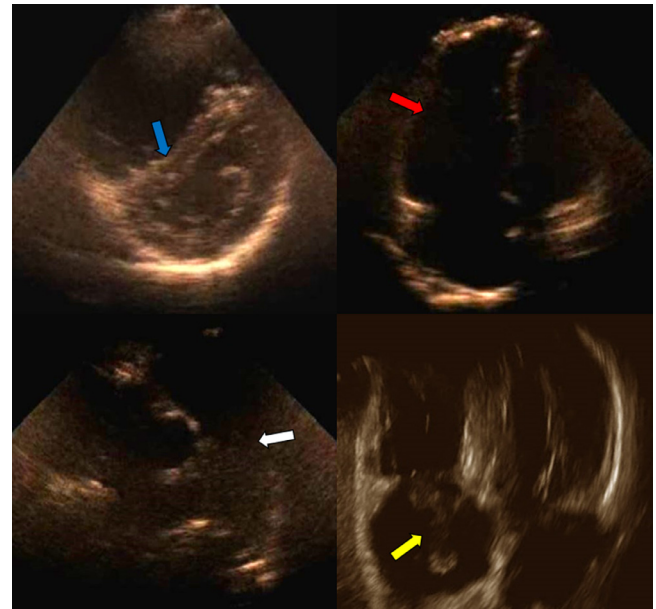


Fig. 3 – The transthoracic echocardiography of the patient. The blue arrow shows D-shape left ventricular; the red arrow shows right ventricular enlargement; the white arrow shows main pulmonary artery enlargement, and the yellow arrow shows a large right atrial clot.

report. This involvement pattern is actually strong evidence pointing out the COVID-19 infection as the main etiology of the thromboembolic event in our patient.

The occlusion of pulmonary artery circulation aggravates disease course and increases the mortality rate in COVID-19 patients [9]. Therefore, preventing thromboembolic events is the first priority in the management of COVID-19 patients. However, the main problem is that there is no specific guideline on how to manage thromboembolism in these patients. Due to the high mortality and morbidity of thromboembolic events, researchers are advised to look for strategies to prevent and manage the early occurrence of thromboembolic events in COVID-19 patients. Dear Editor-in-Chief,

Please see our manuscript submitted on the website entitled “Right Atrial Clot and Pulmonary Embolism in a Patient with COVID-19: A Case Report” for consideration for publication in the Radiology Case Reports. In the article, we have tried to provide an extensive literature review, focusing on the recently raised field of the COVID-19.

The data for this article was prepared with the help of an expert team of academic researchers by the rigorous investigation of the currently available literature. I am currently the assistant professor of the immunology in the department of the immunology at the Zanjan University of Medical Sciences, Iran. The data of the paper were a report about COVID-19 related problem and symptoms.

The authors declared no conflict of interest. I look forward to your positive feedback. Thank you for your kind attention.

REFERENCES

- [1] McGonagle Dennis, O'Donnell James S, Sharif Kassem, Emery Paul, Bridgewood Charles. Immune mechanisms of pulmonary intravascular coagulopathy in COVID-19 pneumonia. *Lancet Rheumatol* 2020;2(7):437–45.
- [2] Lodigiani Corrado, Iapichino Giacomo, Careno Luca, Cecconi Maurizio, Ferrazzi Paola, Sebastian Tim, et al. Humanitas COVID-19 Task Force. Venous and arterial thromboembolic complications in COVID-19 patients admitted to an academic hospital in Milan, Italy. *Thromb Res* 2020;191:9–14.
- [3] Oxley Thomas J, Mocco J, Majidi Shahram, Kellner Christopher P, Shoirah Hazem, Paul Singh I, et al. Johanna T Fifi. large-vessel stroke as a presenting feature of COVID-19 in the young. *N Engl J Med* 2020;382(20):e60.
- [4] Klok F A, Kruip M J H A, van der Meer N J M, Arbous M S, Gommers D, Kant K M, et al. Confirmation of the high cumulative incidence of thrombotic complications in critically ill ICU patients with COVID-19: an updated analysis. *Thromb Res* 2020;191:148–50.
- [5] Middeldorp Saskia, Coppens Michiel, Haaps Thijs F van, Foppen Merijn, Vlaar Alexander P, Müller Marcella C A, et al. Incidence of venous thromboembolism in hospitalized patients with COVID-19. *J Thromb haemost* 2020;18(8):1995–2002.
- [6] Bikdeli Behnood, Madhavan Mahesh V, Jimenez David, Chuich Taylor, Dreyfus Isaac, Driggin Elissa, et al. Global COVID-19 thrombosis collaborative group, endorsed by the ISTH, NATF, ESVM, and the IUA, Supported by the ESC working group on pulmonary circulation and right ventricular function. COVID-19 and thrombotic or thromboembolic disease: implications for prevention, antithrombotic therapy and follow-up: JACC state-of-the-art review. *J Am Coll Cardiol* 2020;75(23):2950–73.
- [7] Bastopcu Murat. Extensive arterial thrombus following discharge after a covid-19 infection. *Ann Vasc Surg* 2021;72:205–8.
- [8] van Dam L F, Kroft L J M, van der Wal L I, Cannegieter S C, Eikenboom J, de Jonge E, et al. Clinical and computed tomography characteristics of COVID-19 associated acute pulmonary embolism: a different phenotype of thrombotic disease? *Thrombosis Res* 2020;193:86–9.
- [9] Oudkerk Matthijs, Büller Harry R, Kuijpers Dirkjan, Es Nick van, Oudkerk Sytse F, McLoud Theresa, et al. Diagnosis, prevention, and treatment of thromboembolic complications in COVID-19: report of the National Institute for Public Health of The Netherlands. *Radiology* 2020;297(1):216–22.