



Contents lists available at ScienceDirect

International Journal of Surgery Case Reports

journal homepage: www.casereports.com

Case-report: A rare cause of intestinal obstruction in late pregnancy

Farzan Dholoo^{a,*}, Amanda Shabana^b, Abbas See^b, Waseem Hameed^c^a Royal Berkshire Hospital, Royal Berkshire NHS Foundation Trust, General Surgery Department, Reading, UK^b John Radcliffe Hospital, Oxford University Hospital NHS Foundation Trust, Oxford, UK^c Wexham Park Hospital, Frimley Health NHS Foundation Trust, General Surgery, Berkshire, UK

ARTICLE INFO

Article history:

Received 24 November 2020

Accepted 29 November 2020

Available online 2 December 2020

Keywords:

Abdominal pain

Caecal volvulus

Sigmoid volvulus

Intestinal obstruction

Signs and symptoms of volvulus

Treatment of volvulus and case report

ABSTRACT

INTRODUCTION: Caecal volvulus represents a rare and often life-threatening cause of intestinal obstruction. Diagnosis and management of caecal volvulus remains a clinical challenge, since those presenting with symptoms can have vague nonspecific presentations. Symptoms eventually occur, usually secondary to obstruction or ischaemia. This case report will discuss the presentation, investigation and management options available.

PRESENTATION: A 31-year-old multigravida, at 38 weeks and 6 days gestation; presented to hospital with a 2-day history of diffuse abdominal pain and distension. Initial examination was unremarkable aside from mild epigastric tenderness. Raised inflammatory markers and concerns for foetal health resulted in an emergency caesarean section. Symptoms however worsened and the patient underwent colonoscopy and computerised tomography (CT) of the abdomen and pelvis with contrast; showing caecal volvulus. The patient was taken to the operating theatres for an emergency right hemicolectomy with formation of end ileostomy. Intra-operatively, areas of necrosis were noted within the caecum suggestive of impending perforation. The patient recovered well post reversal of end ileostomy, with no complications to date.

DISCUSSION: Caecal volvulus represents a rare, but potentially fatal cause of intestinal obstruction and ischaemia. High mortality rates are attributed to delayed diagnosis and treatment. Patients may initially present with vague symptoms, which rapidly progress with the development of ischaemia. Multiple management modalities exist. Central to prognosis is early diagnosis.

CONCLUSION: Early diagnosis and intervention are paramount. Imaging via abdominal x-rays and CT are of particular importance. Surgical management is widely reported as the mainstay of treatment. We advise clinicians to remember this rare diagnosis, as a potential cause of abdominal pain and intestinal obstruction; especially in those with predisposing risk factors.

© 2020 The Authors. Published by Elsevier Ltd on behalf of IJS Publishing Group Ltd. This is an open access article under the CC BY-NC-ND license (<http://creativecommons.org/licenses/by-nc-nd/4.0/>).

1. Introduction

Caecal volvulus is a rare cause of abdominal pain, that can lead to intestinal obstruction, ischaemia and perforation. It is a rare condition affecting approximately 2.8–7.1 million people per year [1]. It accounts for only 1–1.5% of all adult, intestinal obstructions [1]. Despite low prevalence rates; caecal volvulus can lead to perforation and ultimately death if not treated in a timely manner. Caecal volvulus therefore remains an important differential for clinicians to consider. This is especially true in pregnancy, which is an established risk factor for caecal volvulus. We present a unique and interesting case of caecal volvulus; in a young female in her third trimester of pregnancy.

2. Presentation of case

A 31-year-old multigravida, at 38 weeks and 6 days gestation presented to hospital with a 2-day history of diffuse abdominal pain and distension. The patient also reported two episodes of bilious vomiting. There was no past medical history of note and the patient was not taking any regular medications. Her prior pregnancy was unsuccessful. Clinical examination revealed epigastric tenderness and mild abdominal distension, with no signs of guarding or peritonism. Biochemical testing revealed a raised White cell count (WBC) at $20.0 \times 10^9/L$, a raised C-reactive protein (CRP) of 100 mg/L, and a Lactate of 4.0 mmol/L; all other biochemical parameters were within range. Post resuscitation, the patient was transferred to the obstetrics team. Following a normal cardiotocography (CTG) trace, the patient underwent an ultrasound scan (USS), showing a normal uterus and placenta. Erect chest x-ray (Fig. 1A) showed no pneumoperitoneum. The erect chest x-ray was initially thought to represent gastric dilatation. Therefore, a nasogastric tube (NG) was inserted and an urgent oesophago-gastro-duodenoscopy (OGD)

* Corresponding author.

E-mail address: farzan.dholoo@nhs.net (F. Dholoo).

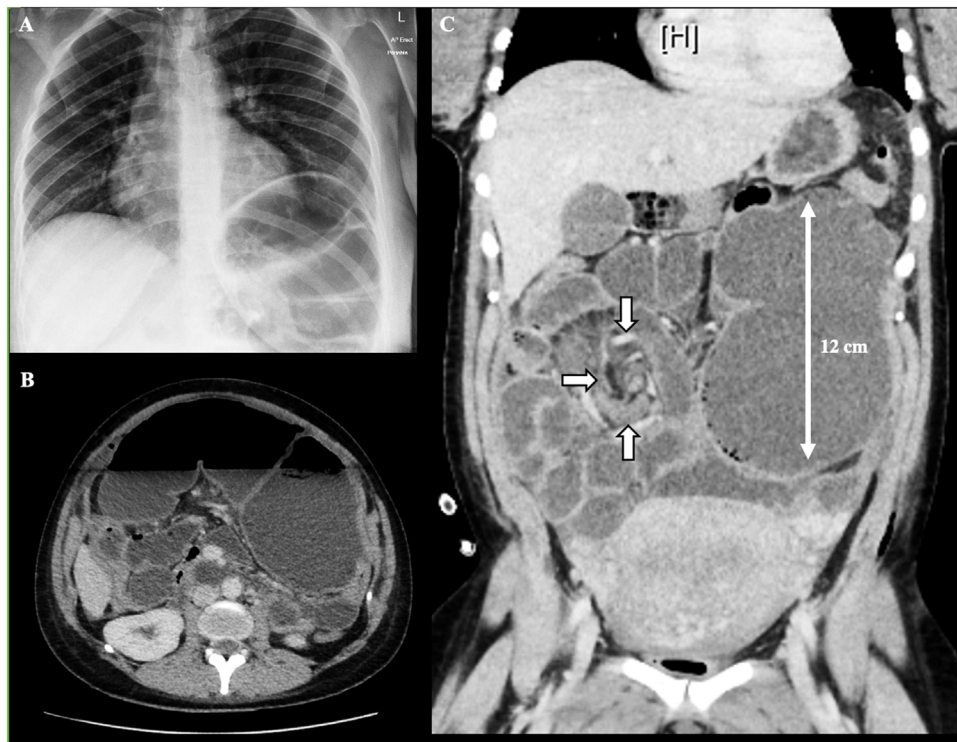


Fig. 1. Erect chest x-ray on admission [A]. Axial [B] and Coronal [C] views, of computerised tomography (CT) of the abdomen and pelvis with contrast. CT demonstrated gross distension of caecum and proximal colon; with associated mesenteric twisting suggestive of caecal volvulus (12 cm). Note the associated 'whirl sign' marked out by three white arrows in Figure C.

arranged. The NG tube drained < 200 mls and symptoms continued. USS of the biliary tract was unremarkable.

As symptoms worsened, and with rising concerns of foetal distress, an emergency caesarean section (C-Section) was performed. During the C-section a surgical opinion was sought. Intra-operative assessment was however limited, due to a large congested uterus and poor access through the pfannenstiell incision. A healthy baby was delivered with no complications.

On subsequent review by a senior surgeon and following re-evaluation of investigations, it was thought that the clinical picture was more likely attributed to a colonic pathology. This correlated with large bowel distension and negligible volumes of NG aspirate. Therefore, in addition to the prearranged OGD, the surgical team also requested an urgent colonoscopy and computerised tomography (CT) of the abdomen and pelvis with contrast.

The performed OGD detected no obvious abnormalities. Colonoscopy demonstrated patchy areas of ecchymosis, mucosal damage and bruising within the transverse colon (Fig. 2). It was thought that the changes present on colonoscopy, were likely secondary to a twisted segment of bowel involving the transverse and right colon. The patient then underwent a CT of the abdomen and pelvis with contrast, to exclude any complications and to rule out a potential tumour or pseudo-obstruction. CT showed gross distension of caecum and proximal colon with associated mesenteric twisting, suggestive of caecal volvulus (Fig. 1B and C).

After reviewing the CT abdomen and pelvis and colonoscopy, a decision was made to consent the patient for a laparotomy and colectomy. Her tachycardia and examination findings of four quadrant peritonism suggested that she was physiologically compromised; due to caecal ischaemia and impending perforation. A conservative approach was not deemed to be safe. The patient underwent an emergency right hemicolectomy with formation of end ileostomy. The operation was performed by a consultant surgeon and registrar. Intra-operatively, serosal tears were noted

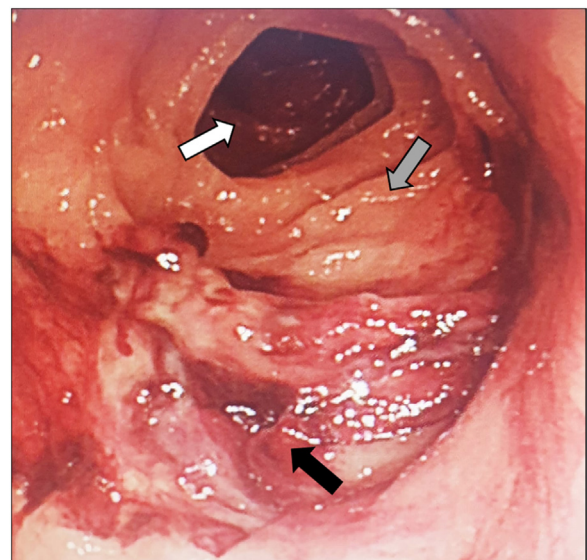


Fig. 2. Image taken during colonoscopy of the mid transverse colon. Colonoscopy demonstrated patchy areas of ecchymosis, mucosal damage and bruising within the transverse colon most likely secondary to repeated twisting. The white arrow depicts proximal transverse colon lumen. The grey arrow represents areas of healthy normal mucosa. The black arrow shows bruised and injured mucosa at the most likely 'twist point'.

along with areas of necrosis; all signs of likely impending perforation (Fig. 3).

The patient recovered well post-operatively and there were no surgical complications. After a short period of post-operative care, the patient was discharged home. Four months later the patient underwent elective surgery for reversal of her end ileostomy. To

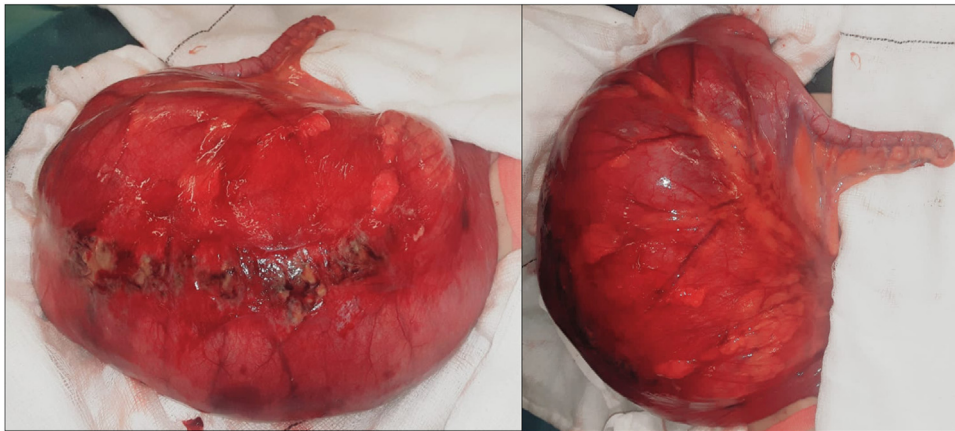


Fig. 3. Images of bowel, taken during the emergency right hemicolectomy with formation of end ileostomy. Intra-operative measurements showed a caecum dilated to approximately 12 cm. Signs of impending perforation were demonstrated by multiple serosal tears in conjunction with areas of necrosis.

date the patient has suffered no complications, with both child and mother progressing well.

3. Discussion

A volvulus by definition, involves the twisting of intestine around itself and supporting mesentery. Volvuli are most common in the sigmoid colon, secondary to twisting of the long sigmoid mesentery. Other rarer sites of volvuli include stomach, transverse colon and caecum. Sigmoid volvulus is by far the most prevalent form of volvuli. Caecal volvulus is a much rarer entity in comparison. In addition to prevalence and anatomical location, an important difference to note is that vascular compromise is more commonly associated with caecal volvulus [6].

Caecal volvulus involves the axial twisting of the distal ileum, caecum and ascending colon on its mesenteric axis, thus causing intestinal obstruction. Torsion usually occurs in a clockwise pattern [1,2]. Delay in diagnosis or treatment, of both sigmoid and caecal volvulus; is associated with high morbidity. Several studies report a mortality rate as high as 30–40%, in patients whom diagnosis and treatment of volvulus are delayed [1–3]. High mortality rates are attributed to the development of a closed loop obstruction, which can subsequently lead to ischemia, perforation, intra-abdominal sepsis and death [3]. It is important to mention the difference between a caecal volvulus, as opposed to a caecal bascule. A caecal bascule is an anatomical variant involving the caecum alone, folding upwards and anteriorly. Both however, present with similar clinical features and indeed share the same high mortality rates [1,2].

Literature suggests that excessive caecal mobility can predispose an individual to the development of caecal volvulus [1]. During development, the caecum migrates to its correct anatomical location in the right lower quadrant. Once migrated there is normally retroperitoneal fixation of the caecum [1,3,4]. Incomplete caecal and ascending colonic fixation, occurs secondary to a lack of embryological development of the dorsal mesentery. This then predisposes patients to potential torsion of the terminal ileum, caecum and ascending colon [5,6].

Several other factors can potentially contribute to the development of caecal volvulus. It is widely established that previous abdominal surgery, pregnancy (in particular during the third trimester), high fibre diets, pelvic masses and chronic constipation can contribute to the occurrence of caecal volvulus [1,3,6–8]. In pregnancy, as the uterus expands it displaces the mobile caecum which can precipitate malrotation [2,4].

It is important to note the variability and indeed vagueness with which volvulus can present. When symptoms occur, they

are usually secondary to either bowel obstruction or ischaemia. Common symptoms therefore include nausea, vomiting and a lack of stool or flatus [9]. In addition, patients may also complain of colicky abdominal pain as well as bloating or distension. Examination findings usually depend on the progression of pathology; early on, one may simply find abdominal tenderness. With development of ischaemia and perforation, one may expect to find signs of peritonitis with a clinic picture of septic shock. Important differentials to consider include pseudo-obstruction, sigmoid volvulus and obstructing malignant lesions.

Literature typically categorises presentation into three main groups; related to the severity, duration and type of rotation [1,7]. The first group, recurrent intermittent, is characterised by intermittent abdominal pain spontaneously resolving. The second, termed acute obstruction, presents in a similar manner to recurrent intermittent, but is defined by a failure to spontaneously resolve. The final group termed, acute fulminant, typically signifies bowel necrosis and its associated pathology [1,7].

Patients with suspected caecal volvulus should have a thorough history, examination and biochemical work-up. Most patients will go on to have an abdominal x-ray which may show some features of caecal volvulus, including caecal dilatation, small bowel dilatation and the absence of gas distally [1]. On abdominal x-ray caecal volvulus typically presents with dilated bowel loops lateral to the midline, as opposed to centrally in sigmoid volvulus. A significant proportion of patients presenting with acute abdominal pain are now imaged via CT. Three radiological findings are pathognomonic for volvulus on CT: ‘coffee bean sign’; ‘whirl sign’; and ‘bird beak sign’ [1,10,11].

One must mention the radiation risk; the aforementioned imaging poses to patient. This is further complicated when considering potential radiation exposure to a developing foetus. CT however should not be delayed in a clinically unwell patient irrespective of radiation, as failure to act within a timely manner could be deleterious. Magnetic Resonance Imaging (MRI) also serves as a further imaging modality with high diagnostic value for volvulus [12].

Owing to the complexity, progression and mortality associated with caecal volvulus, there is little in the way of clinical trials and research for management. It is widely agreed that prompt surgical intervention is the treatment of choice [9]. Multiple other treatment modalities exist including: barium enema; colonoscopy; caecopexy; and colectomy [1]. In cases of perforation or gangrene; resection of the affected segment is the treatment modality of choice [1,4].

Treatment of choice will likely be determined by a variety of factors including biochemical parameters, the patient’s clinical picture, co-morbidities, tissue viability, risk of recurrence and the

potential risks of anaesthesia [1]. It is important to note that conservative management is unlikely to be successful given the low rates of spontaneous resolution, in conjunction with the risk of ischaemia and perforation. One must also note the high recurrence rates associated with conservative management alone [6].

4. Conclusion

We present an interesting case of caecal volvulus in an otherwise healthy 31-year-old multigravida, at 38 weeks and 6 days gestation. A caecal volvulus can present with vague symptoms. When symptoms are present, they are usually attributed to either obstruction or ischaemia. It is important to note that multiple factors, including pregnancy can complicate the investigation and diagnosis of caecal volvulus. Although rare, if missed they are associated with mortality rates as high as 40%.

A detailed history, examination and investigations are essential for both the diagnoses and management of these cases. Surgical management is indeed the recommended treatment of choice. We do note the rarity in incidence of caecal volvulus. Despite this there remains a need to make a prompt diagnosis and deliver appropriate care in any new case of caecal volvulus, due to the risk of ischaemia, perforation and peritonitis. In pregnancy the urgency of the condition underlines the need for a rapid solution, given that two lives are at risk.

Due to low case numbers and the emergency nature of the diagnosis, prospective studies would be impractical to determine optimum timing for emergency surgery. Data however collected retrospectively, would provide other valuable information such as stoma rates (and eventual reversal rates), length of stay, surgical site infection rates and findings of incidental or causative pathology in specimens.

Declaration of Competing Interest

None.

Funding

None.

Ethical approval

The following statement applies for all listed authors:

Appropriate consents, permissions and releases have been obtained from the patient – We have a copy of the signed consent form.

Consent

The following statement applies for all listed authors:

Written informed consent was obtained from the patient for publication of this case report and accompanying images. A copy of the written consent is available for review by the Editor-in-Chief of this journal on request.

We do not have ethics committee approval as this was not a study on multiple patients.

No identifying details are included.

Author contribution

Farzan Dholoo, Amanda Shabana and Abbas See are joint first / primary authors responsible for: Conceptualization; Data curation; Formal Analysis; Investigation; Methodology; Validation; Visualization; Writing the report; Performing the literature search and Referencing the Manuscript.

Farzan Dholoo, Amanda Shabana and Abbas See are to be joint first authors.

Waseem Hameed is the responsible **Consultant** who: Oversaw the project; Edited the manuscript up to submission and Supervised the project.

Registration of research studies

Not Applicable.

Guarantor

Mr Waseem Hameed (General Surgery Consultant).

Provenance and peer review

Not commissioned, externally peer-reviewed.

Other relevant information

Case report is in compliance with SCARE Guidelines [13]

Case report is in compliance with PROCESS Guidelines [14]

Case report is in compliance with PROCESS Criteria [14]

References

- [1] E.T. Consorti, T.H. Liu, Diagnosis and treatment of caecal volvulus, *Postgrad. Med. J.* 81 (December (962)) (2005) 772–776.
- [2] N. Kairys, K. Skidmore, J. Repanshek, W. Satz, An unlikely cause of abdominal pain, *Clin. Pract. Cases Emerg. Med.* 2 (March (2)) (2018) 139–142.
- [3] R. Rabinovici, D.A. Simansky, O. Kaplan, E. Mavor, J. Manny, Cecal volvulus, *Dis. Colon Rectum* 33 (September (9)) (1990) 765–769.
- [4] H. Montes, J. Wolf, Cecal volvulus in pregnancy, *Am. J. Gastroenterol.* 94 (September (9)) (1999) 2554–2556.
- [5] R.L. Rogers, F.J. Harford, Mobile cecum syndrome, *Dis. Colon Rectum* 27 (June (6)) (1984) 399–402.
- [6] C.K. Le, P. Nahiriak, S. Anand, W. Cooper, StatPearls, StatPearls Publishing, Treasure Island (FL), 2020, Sep 18 [Internet] Volvulus.
- [7] J.D. Friedman, M.D. Odland, M.P. Bubrick, Experience with colonic volvulus, *Dis. Colon Rectum* 32 (May (5)) (1989) 409–416.
- [8] G.H. Ballantyne, M.D. Brandner, R.W. Beart, D.M. Ilstrup, Volvulus of the colon. Incidence and mortality, *Ann. Surg.* 202 (July(1)) (1985) 83–92.
- [9] S.S. Bhimji, W. Cooper, Volvulus, in: StatPearls, StatPearls Publishing, Treasure Island (FL), 2018 [Internet] [cited 2019 Jan 20]. Available from: <http://www.ncbi.nlm.nih.gov/books/NBK441836/>.
- [10] C.J. Moore, F.M. Corl, E.K. Fishman, CT of caecal volvulus: unravelling the image, *AJR* 177 (2001) 95–98.
- [11] J.M. Rosenblat, A.M. Rozenblit, E.L. Wolf, R.A. DuBrow, E.I. Den, J.M. Levsky, Findings of cecal volvulus at CT, *Radiology* 256 (July (1)) (2010) 169–175.
- [12] S.S. Atamanalp, Sigmoid volvulus, *Eurasian J. Med.* 42 (3) (2010) 142–147, <http://dx.doi.org/10.5152/eajm.2010.39>.
- [13] R. Agha, T. Franchi, C. Sohrabi, G. Mathew, A. Kerwan, The SCARE 2020 guideline: updating consensus Surgical CAse REport (SCARE) guidelines, *Int. J. Surg.* 84 (2020) 226–230.
- [14] R.A. Agha, M.R. Borrelli, R. Farwana, K. Koshy, A. Fowler, D.P. Orgill, SCARE Group, The process 2018 statement: updating consensus preferred reporting Of CAse Series in Surgery (PROCESS) guidelines, *Int. J. Surg.* 60 (2018) 279–282.

Open Access

This article is published Open Access at [sciencedirect.com](https://www.sciencedirect.com). It is distributed under the [IJSCR Supplemental terms and conditions](#), which permits unrestricted non commercial use, distribution, and reproduction in any medium, provided the original authors and source are credited.